CHAPTER
19 Trauma in children

Learning objectives

To be able to:

- Systematically assess an injured child
- Give examples of how mechanisms of, and responses to, injury differ from those in adults
- Distinguish the elements of the primary and secondary surveys
- Explain when and how to transfuse blood products in children
- Describe some common patterns of injury in children
- Request appropriate investigations for an injured child
- Outline the non-operative management of solid organ injuries
- Outline the principles of the trauma laparotomy and the clamshell thoracotomy
- Explain the principle of damage control surgery

INTRODUCTION

Trauma is the leading cause of death in children over 1 year old, and blunt trauma is the most common mechanism. Prompt, guideline-driven management by a trauma team reduces complications and saves lives. For cranial injuries in children, see ***Chapter 28***; for orthopaedic injuries in children, see ***Part 4, Trauma***.

THE PRIMARY SURVEY

Injured children are assessed using the Advanced Trauma Life Support (ATLS) structured **cABCDE** approach: **c**ontrol of catastrophic bleeding with pressure, **A**irway with C-spine control, **B**reathing with oxygen, **C**irculation with further control of haemorrhage, **D**isability, **E**xposure and Environment. In contrast to managing trauma in adults (see ***Part 4, Trauma***), the following should be considered:

- **A** – overextension of the neck can cause airway obstruction; a neutral position is used for infants and a 'sniffing the morning air' position for older children.
- **B** – hypoxia is usually the cause of cardiac arrest in children; if easily reversed, the cardiac rhythm returns.
- **C** – hypotension occurs comparatively late after 20% of the circulating volume is lost.
- **D** – an age-dependent modified Glasgow Coma Scale (GCS) is used.
- **E** – small children lose heat rapidly, with hypothermia exacerbating any coagulopathy. If their weight in kilograms is unknown, it can be estimated from 2 × (age in years + 4).

In cardiac arrest, the four Hs and four Ts are considered: **H**ypoxia, **H**ypovolaemia, **H**ypothermia/Hyperthermia, **H**yperkalaemia/hypokalaemia, **T**ension pneumothorax, cardiac **T**amponade, **T**oxins, **T**hrombus.

Spinal cord injury without radiological abnormality (SCIWORA)

Cervical hyperextension can occur during a rear impact in a car accident or from a frontal impact to the head. If such a mechanism dissipates a lot of energy, the spinal cord can be damaged even though a cervical radiograph may look normal. Compared with adults, children have a proportionally heavier head and weaker cervical muscles, which together with more elastic spinal ligaments and horizontal facet joints permit displacement without fracture and spontaneous anatomical resolution. A myelopathy can follow a contusion or follow ischaemia from temporary vertebral artery occlusion. If an older child gives a history of transient paraesthesia, numbness or paralysis, cervical immobilisation should be continued, and magnetic resonance imaging obtained. Immobilisation of the cervical spine can be with blocks and tapes or, if tolerated, a collar.

Resuscitation

All children initially receive high-flow oxygen, preferably via a non-rebreathe mask; this can be stopped if there is cardiorespiratory stability after a period of observation. Intubation and ventilation are required if oxygenation is inadequate or if there is a low GCS, combative behaviour, an inability to cooperate, severe burns, prolonged seizures or imminent operative intervention. Ideally, seriously injured children require two large well-secured cannulae. Alongside the antecubital fossa, other suitable veins include the long saphenous at the ankle, the femoral, the external jugular and, in neonates, scalp veins. If intravenous access cannot be established, an intraosseous needle can be placed in the tibia (***Figure 19.1***) or the humeral head, which has the benefit of being easily accessed by an anaesthetist.

Fluid volume resuscitation aims to restore and maintain age-adjusted cardiovascular parameters. Initially, 10 mL/kg of a warmed isotonic fluid is given. Total blood volume (TBV) is around 85 mL/kg in a neonate, rising to 100 mL/kg at 1 month and then falling to 75–80 mL/kg in a child. Major haemorrhage is defined as loss of 50% of TBV in <3 hours, 100% in 24 hours or >20% in <1 hour, but is challenging to assess, especially in blunt trauma. Hospitals should have a major haemorrhage protocol. If the capillary refill is >2 seconds and the child has lost mainly blood, then blood is given, using O rhesus-negative blood until type-specific or cross-matched blood is available. Severe trauma-induced coagulopathy is best managed by correcting specific coagulation factors and using point-of-care testing thromboelastography (TEG) and thromboelastometry (ROTEM), but if these are not available the following are given: packed cells 20 mL/kg, fresh-frozen plasma 20 mL/kg, platelets 10 mL/kg and cryoprecipitate 5 mL/kg, and repeated maintaining these ratios and aiming for a haemoglobin level >80 g/L, platelets $>75 \times 10^9$/L, fibrinogen >1.5 g/L and activated partial thromboplastin time (APTT)/prothrombin time (PT) <1.5 × normal midpoint. If the major haemorrhage occurred within 3 hours, a slow tranexamic acid bolus of 15 mg/kg followed by an infusion (15 mg/kg over 8 hours) should be given.

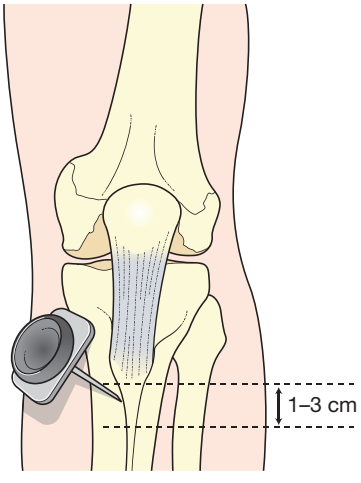

Figure 19.1 The intraosseous needle is inserted into the proximal tibia's medullary cavity about 1–3 cm below the tibial tuberosity.

Trauma-induced coagulopathy

Tissue damage releases factors that encourage coagulation but acidosis and hypothermia prolong it; therefore, blood products should be warmed. For each 1°C fall in temperature, factor activity falls by 10%. Below 34°C clotting times are prolonged, and platelets pool in the spleen and have poor adherence and aggregation. Poor perfusion increases thrombomodulin, which binds to thrombin and activates protein C, so inhibiting cofactors V and VIII. Activated protein C can deplete plasminogen activator inhibitor-1, which results in the formation of plasmin and fibrinolysis. Citrate in blood products can bind to calcium and, if this falls below 0.6 mmol/L, platelets are less effective.

Haemostasis is immature in neonates with procoagulant and anticoagulant proteins, remaining low until 6 months old. Fibrinogen is qualitatively dysfunctional, existing in a fetal form for 6–12 months after birth and contributing to an increased risk of bleeding. Burns can also cause a consumptive coagulopathy with microangiopathic haemolysis.

Children are more susceptible to hypothermia than adults: wet clothes should be removed early and warming blankets used. Children are more likely to become hypoglycaemic after a major injury as they mobilise glycogen poorly – blood sugar should be monitored in the significantly injured child, especially if they are nil by mouth.

A nasogastric tube and a urinary catheter should be considered for children who have had a major abdominal or head injury or are unconscious or ventilated. An orogastric tube is used if there is suspicion of a basal frontal skull fracture and a suprapubic catheter if a urethral injury is suspected.

Injury Severity Score

An Injury Severity Score (ISS) (see *Chapter 26*) >15 predicts mortality in adults, but children require an ISS >25 for the same prediction; this is because most children have an isolated head or extremity injury. Only around 10% of children have multiple injuries.

- **Head**: in a neonate, the fontanelle or 'soft spot' may not have closed, leading to a bony space that could be confused with a fracture. A bulging fontanelle may suggest raised intracranial pressure, whereas a sunken fontanelle is seen in hypovolaemia.
- **Chest**: a child's rib cage is very compliant and ribs may bend and recover rather than break, leading to lung contusions or mediastinal injuries without fractures. If diagnosed clinically, a tension pneumothorax need not be confirmed with a chest radiograph before needle thoracocentesis and placing a chest drain. Although uncommon, cardiac tamponade should be considered and requires an emergency subxiphoid needle pericardiocentesis; a limited echocardiogram may confirm the diagnosis.
- An emergency department clamshell thoracotomy should be performed for penetrating chest injury where the patient had a witnessed arrest within the last 15 minutes. An incision is made across the chest in the fifth intercostal space. It may be possible to cut the sternum with scissors rather than needing a Gigli saw. The pericardium is opened, blood removed and bleeding controlled. A hole in the heart can be oversewn, taking care to avoid the coronary vessels. If the bleeding appears to be from lung, the lung can either be rotated 180° (lung twist) or the hilum slooped. The aim is not to perform a definitive repair but to buy time, allowing resuscitation, including internal massage until cardiac output returns. The clamshell thoracotomy also allows compression of the aorta just above the diaphragm to aid vascular filling.

Leonardo Gigli, 1863–1908, Florentine surgeon and obstetrician.

- **Abdomen**: the liver and spleen in children are less well protected by the rib cage than they are in adults and are at greater risk of injury from blunt trauma. Signs may be subtle, and tenderness should be investigated with cross-sectional imaging. If there is significant abdominal bleeding, aortic compression may be helpful, and this may be easier to achieve through a thoracotomy than a laparotomy; it can be challenging to reach the aorta above the liver.
- **Extremities**: in comparison with adults, children's bones are more compliant – they may bend or fracture one cortex. Children's bones also remodel as they grow; therefore, the position of an angled distal limb fracture may be accepted in a child when it would be manipulated in an adult. The growth plates in children are not yet fused and a fracture involving the growth plate can limit future limb growth – these fractures should be referred to a paediatric orthopaedic surgeon.

SECONDARY SURVEY

The secondary survey is performed after resuscitation and stabilisation. The history is reviewed and a complete clinical examination is performed to assess for other injuries.

Imaging

The choice of imaging depends on the mechanism of injury and the findings on examination. Cross-sectional imaging can be invaluable, but a head-to-toe computed tomography (CT) scan should only be performed with good reason to limit exposure to ionising radiation.

Plain radiograph

A chest radiograph is mandated in major trauma. The cervical spine is rarely injured, but if the injury mechanism leads to suspicion of cervical damage, then a cervical spine series is requested. Lateral and anteroposterior images must include the base of the skull and the C7–T1 junction. The odontoid or 'peg' projection can be difficult to obtain as the mouth needs to be open for the anteroposterior projection to see C1 (atlas) and C2 (axis). A pelvic radiograph is requested if a pelvic fracture is suspected. Suspected limb fractures initially undergo anteroposterior and lateral radiographs with CT reserved for those that are complex.

CT scans

A head CT scan should be performed within 1 hour if the GCS is <14 at the initial assessment or within 2 hours if the GCS is <15 after the injury. Other indications include a tense fontanelle, suspicion of an open or depressed skull fracture or a basal skull fracture, abnormal pupillary response, abnormal posturing, a focal neurological defect or concern about a non-accidental injury. A head CT scan should also be performed if there are three or more vomiting episodes, a witnessed loss of consciousness for >5 minutes or amnesia >5 minutes.

A CT scan of the chest, abdomen and pelvis is performed if there is abdominal wall bruising (*Figure 19.2*), tenderness, distension, peritonitis, blood per rectum or blood in the nasogastric tube. Some relative indications include an aspartate aminotransferase >200 U/L, amylase >100 U/L or microhaematuria >5 erythrocytes/high-power field. Abdominal and pelvic CT should be single-volume dual-contrast to minimise radiation exposure using the Camp Bastion or Afghan protocol.

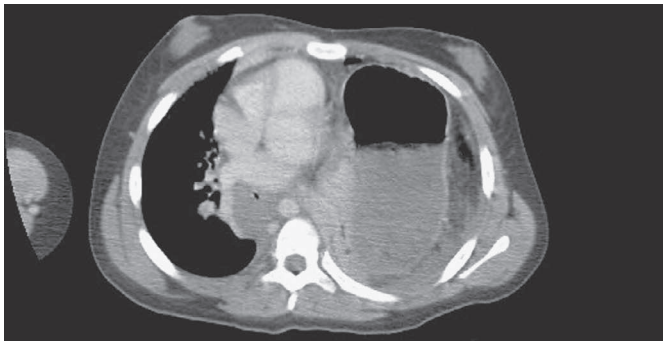

Figure 19.2 Traumatic diaphragmatic rupture found in a child with abdominal wall bruising.

A CT scan of the chest should be performed after a penetrating chest injury or a significant deceleration. However, most blunt chest injuries are detected on a chest radiograph; if the mediastinal silhouette is normal, a chest CT is not usually required.

A focused abdominal sonography trauma (FAST) scan is not helpful in children as the findings can be difficult to interpret.

Patterns of injury

There are some well-recognised patterns of injury in children.

Lap belt

If a child experiences a forced flexion over a lap belt in a car accident, the small bowel or its mesentery or the bladder's abdominal portion may get compressed against the spine. These tissues may fail up to 72 hours after the injury. Lumbar fractures may also be seen. In small children, the pancreas can be compressed by a lap belt.

Handlebar injury

A child who falls onto the end of a bicycle handlebar may crush the pancreas, duodenum, small intestine or its mesentery against the spine. A duodenal haematoma may cause an obstruction, the pancreas may be injured or divided and contused intestine may perforate after a delay of a few days, so a period of observation is required. When this injury pattern is seen in a child under 3 years old, a non-accidental injury must be considered.

Straddle injury

A child typically falls onto the side of a bath or a toy, causing a perineal injury that may involve the urethra or vagina.

Non-accidental injury

Non-accidental injuries should be suspected when the reported mechanism of injury or its timing are unusual. Fractures,

abdominal injuries and intracranial haemorrhages in those under 2 years old are often non-accidental. Bruises are remarkably difficult to date, but their shape and pattern may distinguish accidental from abusive bruising if they leave an imprint. Patterned bruises generally do not occur during regular play. Bruises over soft tissues in an immobile infant are suspicious, whereas those over bony prominences such as the knees, elbows and the forehead in a mobile child are not. Bruises on the cheeks, neck, genitals, buttocks and back are unlikely to be accidental. Some benign entities may be confused with abusive bruises, such as Mongolian spots and haemangiomas. Children with idiopathic thrombocytopenic purpura or leukaemia may present with unexplained bruises in different stages of healing.

DEFINITIVE MANAGEMENT

Chest

A small pneumothorax detected on a chest radiograph may be observed rather than drained. Lung contusions require analgesia and chest physiotherapy to prevent secondary infection. Penetrating lung injuries may be assessed at either thoracoscopy or thoracotomy and the underlying lung injury sealed with fibrin glue or by applying a stapler; segmentectomy or lobectomy are rarely required.

Abdomen

Intraperitoneal air mandates a laparoscopy or laparotomy. Penetrating wounds that have not entered the abdominal cavity should be cleaned and closed. The spleen and liver account for 70% of all visceral injuries caused by blunt trauma. In the haemodynamically stable child, most solid organ injuries can be managed without an operation, but if unstable despite appropriate transfusion, or only transiently responding, interventional radiology and embolisation or a laparotomy should be considered. Recurrent instability may reflect an inadequate initial resuscitation, and the need for a second transfusion does not mandate an operation.

Following an abdominal solid organ injury, bed rest is advised until pain free, with mobilisation after a minimum of 1 night for grade I and II injuries and after a minimum of 2 nights for grade >III injuries. High-impact activities and contact sports should be limited for grade IV and V injuries for 6 weeks. However, delayed haemorrhage can arise spontaneously several days after an injury and is thought to occur in a hyperosmolar setting when a haematoma breaks down. Discharged patients need to know to return to the hospital if unwell.

TABLE 19.1 Spleen injury scale.

Grade	Injury type	Description of injury
I	Haematoma	Subcapsular, <10% surface area
II	Laceration	Capsular tear, <1 cm parenchymal depth
	Haematoma	Subcapsular, 10–50% surface area, intraparenchymal, <5 cm in diameter
III	Laceration	Capsular tear, 1–3 cm parenchymal depth not involving a trabecular vessel
	Haematoma	Subcapsular, >50% surface area or expanding; ruptured subcapsular or parenchymal haematoma, intraparenchymal haematoma ≥5 cm or expanding
IV	Laceration	>3 cm parenchymal depth or involving a trabecular vessel
	Laceration	Laceration involving segmental or hilar vessels producing major devascularisation (>25%)
V	Laceration	Completely shattered spleen
	Vascular	Devascularised by a hilar injury

TABLE 19.2 Liver injury scale.

Grade	Injury type	Description of injury
I	Haematoma	Subcapsular, <10% surface area
	Laceration	Capsular tear, <1 cm parenchymal depth
II	Haematoma	Subcapsular, 10–50% surface area, intraparenchymal, <10 cm in diameter
III	Haematoma	Subcapsular, >50% surface area or expanding; ruptured subcapsular or parenchymal haematoma; intraparenchymal haematoma ≥10 cm or expanding
	Laceration	>3 cm parenchymal depth or involving a trabecular vessel
IV	Laceration	Parenchymal disruption involving 25–75% of hepatic lobe or 1–3 Couinaud segments in a single lobe
V	Laceration	Parenchymal disruption involving >75% of hepatic lobe or >3 Couinaud segments within a single lobe
	Vascular	Juxtahepatic venous injuries
VI	Vascular	Hepatic avulsion

Specific considerations

Spleen

There is a risk of splenic pseudoaneurysm after splenic trauma, which is unrelated to the severity of the injury (*Table 19.1*). Therefore, a follow-up ultrasound is recommended.

Liver

The grades of liver trauma are given in *Table 19.2*. Bile leaks are rare and often resolve after drainage rather than repair but should be discussed with a paediatric liver surgeon.

Claude Couinaud, 1922–2008, French surgeon and anatomist, described the segmental anatomy of the liver.

Pancreas

Pancreatic trauma may lead to a pancreatic pseudocyst, which requires endoscopic drainage into the stomach. For distal lacerations in the pancreatic tail, some surgeons prefer an early distal pancreatectomy rather than non-operative management. Proximal pancreatic duct injuries in older children can be stented.

Renal

After severe renal injuries, hypertension can develop, which may need treatment. A dimercaptosuccinic acid (DMSA) scan is used to assess function in those with hypertension or following grade IV or V injuries (*Table 19.3*).

TABLE 19.3 Renal injury scale.

Grade	Injury type	Description of injury
I	Contusion	Microscopic or gross haematuria. Normal imaging
	Haematoma	Subcapsular, not expanding and without parenchymal laceration
II	Haematoma	Non-expanding peri-renal haematoma confined to the retroperitoneum
	Laceration	<1.0 cm parenchymal depth without extravasation of urine
III	Laceration	>1.0 cm parenchymal depth without collecting system rupture or extravasation of urine
IV	Laceration	Parenchymal laceration extends through the cortex, medulla and collecting system
	Vascular	Main renal artery or vein injury with contained haemorrhage
V	Laceration	Shattered kidney
	Vascular	Avulsion of the renal hilum devascularising the kidney

Duodenum

A duodenal haematoma has a risk of late perforation, which may be retroperitoneal. Therefore, a second abdominal CT scan or a contrast study should be considered if there is deterioration or recovery is particularly slow.

Bowel

There are three mechanisms: the bowel wall may fail instantly if pressure rises rapidly in a trapped loop, it may fail up to 72 hours after a direct crush injury or it may become ischaemic following a mesenteric injury damaging its blood supply.

Urethral injury

In straddle injuries and pelvic fractures there may be blood at the urethral meatus. Urethral catheterisation can aggravate a urethral injury, and so a suprapubic catheter should be placed.

DAMAGE CONTROL SURGERY

Damage control surgery aims to break the 'vicious cycle' of hypothermia, tissue hypoxia, coagulopathy and acidosis before later definitive repair. Anatomy is restored when the physiology is optimised. The principles are in sequence: (i) short operations aiming to control haemorrhage and limit contamination; (ii) ongoing correction of deranged physiology – acidosis, hypothermia, perfusion and organ function on intensive care; (iii) definitive surgical repair.

In a trauma laparotomy, a midline incision is made from the xiphisternum to the pubic symphysis. Large clots are removed and the abdomen is packed in all four quadrants with large swabs to tamponade bleeding. If packing does not control bleeding, it is either inadequate packing, and more should be applied, or there is a significant arterial bleed, and so pressure should be applied to the aorta above the liver. Once bleeding is stemmed and the intravascular volume restored, the packs are removed systematically one quadrant at a time to find the source of the bleeding. Control is by vessel repair, ligation or removal of the organ or reapplication of the packs. Contamination is controlled by either repairing a simple bowel injury with a continuous suture or resection of multiple areas of perforated bowel with a clip-and-drop technique (either stapling or tying off the ends but not attempting primary anastomosis). Bile injuries are managed with a drain, and bladder injuries are oversewn and a urethral catheter placed. The abdomen is left open, allowing transfer to critical care for ongoing physiological correction before returning to theatre in the following days for further procedures.

Summary box 19.1

Paediatric trauma

- Use the Advanced Trauma Life Support (ATLS) guidelines
- Overextension of the neck can compromise the airway
- Cervical spine injury can be present without radiographic signs
- Intraosseous access is helpful in small children
- Lung contusion can occur without rib fractures
- In a stable child, abdominal injuries are best assessed by CT
- Blunt abdominal organ injury can usually be managed non-operatively
- Damage control surgery aims to correct physiology before definitive repair